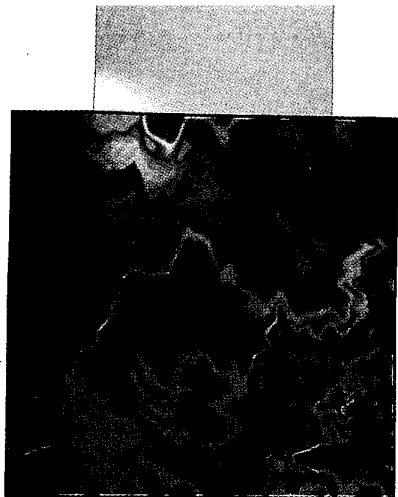

The Important Role of Infrared Imaging in Breast Cancer

New Technology Improves Applications in Risk Assessment, Detection, Diagnosis, and Prognosis

Early studies of infrared (IR) imaging of the breast, commonly called thermography in medicine, were initiated in both Europe and the United States in the 1970s and concentrated on the diagnosis of breast cancer. From 1973 to 1981, the National Cancer Institute (USA) sponsored the Breast Cancer Detection Demonstration Projects (BCDDP). These studies were designed to test the role of both IR imaging and mammography in the diagnosis of breast cancer. However, IR imaging was discontinued very early in the study. The premature closing of the IR imaging of the breast in the BCDDP study was due to technical difficulties, lack of training of technical staff, lack of experience in reading by professional staff, lack of standardization of equipment, and lack of interest in this new technology by radiologists.

The closure resulted in there being no clear demonstration of the possible importance of IR imaging in the diagnosis of breast cancer. Other consequences of discontinuation of this part of the study was that no data were collected to compare the diagnostic ability of mammography with IR imaging, to evaluate IR imaging as an indicator of risk of developing breast cancer, or to evaluate this imaging modality as a prognostic indicator in patients with abnormal mammograms who later were surgically biopsied and diagnosed with breast cancer.

After the BCDDP discontinued their study of IR imaging, several studies were published supporting the role of IR imaging as a high-risk marker for breast cancer [1, 2], in the diagnosis of breast cancer [1, 2, 3], and as a prognostic indicator for breast cancer patients [3, 4]. The results reported in this article further support the

use of IR imaging in risk assessment, detection, and as a prognostic indicator. We present preliminary evidence showing that the improvements in technology that have been incorporated into second-generation, focal-plane, indium-antimonide detector systems can significantly improve breast IR images.

Methods

The normal and breast cancer patients in the first part of this study were selected from patients who had undergone breast IR imaging as part of their breast examination at the Elliott Mastology Center beginning in 1973. These exams also included mammography and clinical examination. The study included three categories of patients: (1) 126 patients who died of breast cancer during this period and had breast IR imaging within the one-year period leading up to diagnosis of their breast cancer, (2) 100 randomly selected living breast cancer patients who also had IR imaging within the one-year period previous to their diagnosis of breast cancer, and (3) 100 patients who had a variety of mastopathies but had not been diagnosed as having breast cancer during screening. If, during IR imaging examination, asymmetric heat patterns (diffuse heat, focal hot spots, areolar and/or periareolar heat, vessel discrepancy, or edge signs) were noted, the patient was considered at high risk of getting breast cancer or to have a poor prognosis, if already diagnosed. Clinical/pathological staging (tumor size, nodal status, presence of metastasis), age, and location of the cancer were also documented for all these patients, and the results were compared to IR imaging results.

Jonathan F. Head, Fen Wang,
Charles A. Lipari, Robert L. Elliott
Medical Thermal Diagnostics, Baton Rouge

A second group of patients, being screened with mammography, also underwent IR imaging of their breasts. During the study, normal and high-risk patients had IR images of their breasts taken with an Inframetrics (North Billerica, MA) scanning mercury-cadmium-telluride detector system (right oblique, left oblique, and frontal views) and recorded as hard-copy photographic images (a color frontal isotherm view, and three black and white views: frontal, left oblique, and right oblique). For comparison, three additional breast views (frontal, right oblique, and left oblique) were recorded with an Amber (Raytheon, Inc., Dallas, TX) focal-plane, indium-antimonide, staring array system. IR images of 220 patients from both the scanning and focal-plane systems were digitized and stored on computer hard disk, thus creating a digitized IR image database for later image analysis.

Results

When the IR imaging results were grouped into the three groups of screened, cancer, and deceased cancer patients, there was a significantly greater percentage of abnormal IR images in breast cancer patients than in women being screened who were at normal or high risk of developing breast cancer (Table 1). There was a 28% incidence of abnormal IR images in screened patients and a significantly greater incidence at diagnosis, 65%, for living breast cancer patients. The 88% incidence of abnormal IR images at diagnosis in the deceased breast cancer patients was also significantly higher than the 65% incidence of breast cancer patients in general. The data in Table 1 show that the increasing incidence of abnormal IR images is significantly related to the likelihood of progression of the disease. Thus, IR imaging results, which are useful for risk assessment, also have prognostic significance.

The prognostic significance of the components of the clinical/pathological staging system has previously been demonstrated in breast cancer patients. In this study, we found that nodal status and presence of metastatic disease were not related to IR imaging results. However, clinical tumor size (diameter of palpable mass), but not pathological tumor size (diameter of cross section of mass after surgical removal), was significantly related to IR findings, which resulted in patients with larger tumors being more likely to have an abnormal IR image (Table 2).

Even though patients with larger tumors were more likely to have abnormal IR images, it is important to note that the group of patients with the smallest tumors (T1) also had over 50% abnormal IR images. The age of the patients (less than 50 compared to greater than or equal to 50) and location of the tumor (left compared to right breast) were also found to be independent of and therefore unrelated to IR imaging results.

Table 3 presents the results from 20 cancer patients in this study who had serial IR imaging and had at least one IR image a minimum of one year before being diagnosed with breast cancer. These 20 patients had IR results at diagnosis that are representative of the larger group that they were selected from, in that 50% (10 of 20 patients) had abnormal IR images, which is similar to the 65% (65 of 100 patients) with abnormal IR images from Ta-

Table 1. Breast Infrared Imaging Results for Screened, Cancer, and Deceased Patients

Infrared Imaging Results	Patients		
	Screened	Cancer	Deceased
Normal	72 72%	35 35%	15 12%
Abnormal	28 28%	65 65%	111 88%

p < 0.0001, chi-square analysis for independence

Table 2. Comparison of Clinical Tumor Size and Infrared Imaging Results

Infrared Imaging Results	Clinical Size Classification		
	T1 (<2cm)	T2 (2-5 cm)	T3 (>5 cm)
Normal	9	14	0
Abnormal	10	31	10
% Abnormal	53	69	100

p < 0.05, chi-square analysis for independence

Table 3. Infrared Imaging Results of Patients Who Had an Infrared Image of Their Breasts at Least One Year Before Diagnosis and at Diagnosis of Breast Cancer

Infrared Image Results at Least One Year Prior to Diagnosis	Infrared Image Results at Diagnosis	
	Normal	Abnormal
Normal	10	3
Abnormal	0	7

p < 0.005, chi-square analysis for independence

Table 4. Length of Time of Follow-Up

>1 Year Before	Infrared Imaging Results At Diagnosis	Number of Patients	Follow-up Time in Months		
			Mean ± SD	Median	Range
Abnormal	Abnormal	7	95 ± 46	87	18-158
Normal	Normal	10	90 ± 30	95	24-123
Normal	Abnormal	3	34 ± 19	24	23-56

Second-Generation System	First-Generation System		
	Subjective Thermographic Diagnostic Classification		
Infrared Index	Normal	Slightly Abnormal	Abnormal
0	87/220 (39.5%)	12/220 (5.5%)	10/220 (4.5%)
1	23/220 (10.5%)	5/220 (2.3%)	4/220 (1.8%)
2	22/220 (10.0%)	16/220 (7.3%)	10/220 (4.5%)
3	10/220 (4.5%)	1/220 (0.5%)	4/220 (1.8%)
4	5/220 (2.3%)	0/220 (0.0%)	6/220 (2.7%)
5	1/220 (0.5%)	1/220 (0.5%)	3/220 (1.4%)

p = 0.0001, chi-square analysis for independence

ble 1. All 10 of the patients who had normal IR images at diagnosis had normal IR images at least one year before diagnosis. A large proportion (70%) of the patients who had abnormal IR images at diagnosis had abnormal IR images at least one year prior to diagnosis. A small proportion (30%) of patients with abnormal IR images at diagnosis previously had normal IR images.

The average times between earliest positive or negative IR images and diagnosis are presented in Table 4. The seven patients with abnormal IR images at diagnosis, who also had abnormal IR images at least a year earlier, had abnormal IR images for an average of almost eight years. The 10 patients with normal IR images at diagnosis had normal IR images for an average of seven and a half years. The few patients who changed from normal to abnormal IR images at diagnosis had normal IR images at least 23 months before diagnosis.

In the second part of the study, the second-generation, focal-plane, staring array system was found to produce much

higher quality images than the first-generation scanning system. The first decision made was to try to quantitate the six individual asymmetric abnormalities present in the focal-plane images and to create an IR index by adding together the individual scores for each abnormality (small hot spot, score = 1; large hot spot, score = 2; global heat, score = 3; vascular heat, score = 1, 2, 3; areolar heat, score = 1; edge heat, score = 1). The images from the focal-plane staring array had IR indexes that could range from zero to eight, but the highest index computed was five. Previously, scanning IR images were considered abnormal if any of the six asymmetric abnormalities were present, and images that only had a borderline IR asymmetry were called slightly abnormal (three levels of results: normal, slightly abnormal, abnormal).

The IR indexes derived from the second-generation, focal-plane imaging results were compared to the levels of abnormality from the scanning results on the patients being screened for breast can-

cer (Table 5). Chi-square analysis for independence showed that the two methods produced results that were strongly associated ($p = 0.0001$). The most interesting result was an increase in the sensitivity for asymmetric heat patterns with the focal-plane system: 50.5% (111 of 220) of the patients without breast cancer had abnormal IR images, whereas only 32.7% (72 of 220) of the patients had asymmetric heat patterns with the first-generation scanning system. Analysis of the six asymmetric abnormalities individually (Table 6) showed that most of the increase in sensitivity could be attributed to a significant ($p = 0.0054$) increase in vascular asymmetry from 43 of 218 patients with the scanning system to 70 of 220 with the focal-plane system.

Next, the distribution of the IR index was compared to the levels of abnormality from the scanning images to determine if the increase in sensitivity of the second-generation technology would create small subsets with higher IR indexes that could be used to refine risk assessment. When an IR index of 1 is considered to be so insignificant that a patient's risk of getting breast cancer is not increased, and 2 is considered to only slightly increase risk, then 14.1% (31 of 220) of the patients being screened for breast cancer would be categorized at high risk. On the other hand, 37 of 220 patients had abnormal IR images with the scanning system, which means that 16.8% of the screened patients would be at high risk (Table 5).

Three known risk factors (family history of breast cancer, previous estrogen hormone therapy, and previous breast biopsy) were compared to the IR results from the first-generation scanning and second-generation focal-plane systems (Table 7). None of these risk factors was found to correlate with IR imaging results

Abnormality	First-Generation System (Scanning)	Second-Generation System (Focal Plane)
Asymmetric Small Focal Hot Spot	41/218 (18.8%)	28/220 (12.7%)
Asymmetric Large Focal Hot Spot	3/218 (1.4%)	35/220 (15.9%)
Asymmetric Global Heat	6/218 (2.8%)	2/220 (0.9%) $p = 0.1434$
Asymmetric Vascular Heat	43/218 (19.7%)	70/220 (31.8%) $p = 0.0054$
Asymmetric Areolar Heat	6/218 (2.8%)	14/220 (6.4%)
Asymmetric Edge Heat	1/218 (0.5%)	0/220 (0.0%)

from either system. Therefore, IR imaging results were an independent risk factor in breast cancer. The physician also assigned patients being screened into normal and high-risk categories by subjectively integrating family history, mastopathy, previous use of estrogen hormones, and previous breast biopsy (Table 7). The results of this physician-integrated risk assessment was also not related to the results from either IR imaging system.

The final part of the study was an attempt to apply image processing and computer-vision techniques to produce objective measures of asymmetric heat patterns. Preliminary results showed that comparative pixel statistics (mean, standard deviation, median, minimum, maximum temperatures) could be computed for complete breasts, quadrants of the breast (Fig. 1, schematic; Fig. 2, IR image of breasts), and hot spots.

Discussion

To date, IR imaging of the breast has not been adequately studied for conclusions to be drawn about its role in the detection and treatment of breast cancer. In the BCDDP, IR imaging was originally included in the study, but it was quickly discontinued without collection of the data necessary to determine its value in detection and diagnosis of breast cancer. The high false positive rate (found to be 28% in the present study) of IR imaging compared to mammography in women being screened for breast cancer has always been considered a major drawback. The combination of this high false positive rate with the inability of IR imaging to localize a lesion or tumor (abnormalities found by IR imaging do not define an area that can be surgically biopsied) has been sufficient reason to prevent breast IR imaging from becoming a routine procedure.

The high false positive rate of IR imaging of the breasts does suggest that this technique might be useful in defining a group of patients at high risk for developing breast cancer. Many of the women who are undergoing mammography and IR imaging at our breast clinic are symptomatic, have a family history of breast cancer, or have abnormalities discovered by their primary care physicians. Therefore, their risk exceeds the 10% lifetime risk/occurrence of breast cancer for women in the general population. Gautherie and Gros [1] showed that 38% (298/784) of patients with abnormal IR images were diagnosed with breast cancer

Infrared imaging results, which are useful for risk assessment, also have prognostic significance.

in the four-year period following the abnormal IR images. Stark [2] found that 23% of patients with abnormal IR images developed breast cancer within 10 years. In the present study, the significantly ($p < 0.0001$, chi-square analysis for independence) higher percentage (65%) of patients with abnormal IR images at the time of breast cancer diagnosis compared to the 28% rate of abnormal IR images in the screening group of normal and high-risk patients suggests that an abnormal image is a high-risk marker in breast cancer. Of the screened patients, a much higher proportion (approximately a two- to three-fold increase in risk) with abnormal IR images will develop breast cancer, as compared with those with normal images. This suggestion is reinforced by the data in Table 4, where it can be seen that 35% (7/20) of the cancer patients had abnormal IR images 18 to 158 months prior to their diagnosis of breast cancer. These studies all provide strong evidence that breast IR im-

aging, an inexpensive and completely noninvasive procedure, has an important role in defining a group of women at high risk for breast cancer. These patients at increased risk of developing breast cancer should have mammography, IR imaging, and clinical examination more frequently, in an attempt to diagnose at an earlier and more curable stage.

Since the mid 1980s, breast cancer researchers have been searching for clinical, pathological, and biochemical characteristics that can be integrated to provide a rational basis of selecting node-negative (absence of spread of the breast cancer to the axillary lymph nodes) patients for adjuvant chemotherapy. It is known that breast cancer will not recur (and cause death) in approximately 90% of node-negative patients with tumors less than 2 cm in diameter. However, in the 10% where recurrence occurs, the cancer will be less responsive to chemotherapy than it would have been in the adjuvant setting. IR imaging appears to provide prognostic information that could be used in combination with other clinical, pathological, and biochemical parameters in the selection of those patients for adjuvant chemotherapy. Isard, et al. [4], in a study of 70 breast cancer patients, showed that 30% of patients with abnormal IR images survived five years, compared to 80% of patients with normal IR images. The present study showed that 65% of the breast cancer patients had abnormal IR images, but a significantly ($p < 0.0001$) greater proportion (88%) of those who had died of breast cancer had abnormal IR images. This significantly greater proportion of deceased breast cancer patients with abnormal IR images is further evidence to support IR imaging as a prognostic indicator.

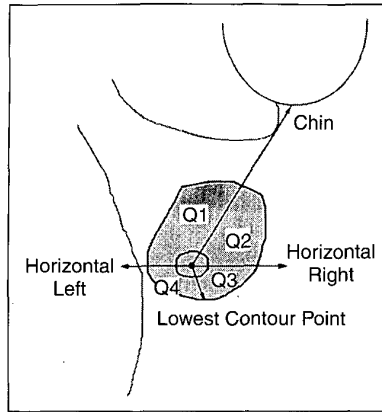
Table 7. Comparison of Results of First- and Second-Generation Infrared Imaging to Known Risk Factors in Breast Cancer

Risk Factors	First-Generation Scanning Infrared Imaging System		Second-Generation Focal-Plane Infrared Imaging System	
	p	n	p	n
Family History	0.3903	213	0.7971	213
Previous Estrogen Therapy	0.5357	210	0.8875	210
Previous Breast Biopsy	0.0747	212	0.3582	212
Physician's Subjective Integration	0.2399	220	0.9522	220

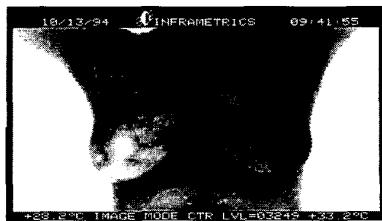
p = probability, n = number of cases compared; chi-square analysis for independence

Although IR imaging of the breast has been shown to have prognostic value, it is important to determine if such results have value independent of other previously identified prognostic indicators. We have previously reported that when IR imaging was done at the same time as diagnostic mammography (prior to diagnostic needle or surgical biopsy for breast cancer) and compared to the size, nodal status, and presence of metastatic disease of the TNM classification system (T, tumor size; N, nodal status; M, presence of metastatic disease), then IR imaging results were only related to clinical tumor size (see Table 2). It is important to note that even though the percentage of patients with abnormal IR imaging increased with increasing tumor size, over 50% (10 of 19) of the patients with small tumors (less than 2 cm in diameter) had abnormal IR images. This finding suggests that the risk of recurrence could be related to IR imaging results even in the group of patients with tumors less than 2 cm in diameter. When looking at all stages of breast cancer, IR imaging results were independent of nodal status, but we do not, as yet, have enough Stage I (a tumor less than 2 cm in diameter, negative lymph nodes, and free of metastatic disease) patients to analyze IR imaging results for disease-free and overall survival in relation to adjuvant chemotherapy. Head, et al. [3], also showed that IR imaging results were unrelated to age, tumor location (right or left breast), and estrogen and progesterone receptor status. Many more patients will have to be analyzed to determine if IR imaging is an independent and useful prognostic indicator. We feel that this would be a worthwhile pursuit considering the small cost and noninvasive nature of IR imaging.

The growth rate of breast cancers, determined by measuring the change in diameter of breast tumors over time and by calculating tumor volume doubling times, has been shown to be one of the best predictors of disease-free and overall survival and therefore is a good prognostic indicator. However, the clinician is rarely able to follow a growing tumor in individual patients over a long enough period of time to determine the volume doubling time. It will be necessary to find a more practical method of approximating growth rate or other more easily determined prognostic indicators that are highly correlated to and dependent on it. Tumor growth rate [5], tumor ferritin con-



1. Guidelines for breast quadrants.



2. Abnormal infrared image of the breasts.

centration [3], proliferation index by flow cytometry [3], and semiquantitation of the proliferation-associated antigen Ki-67 in frozen sections by immunocytochemistry [3] have all been shown to be related to IR imaging results. The correlation of growth rate and these proliferation-related parameters with IR imaging results suggests that a breast cancer patient with an abnormal IR image has a higher probability of having a fast-growing tumor with increased blood flow to it and its immediately surrounding tissue. This increased blood flow is necessary to bring the nutrients required to maintain the growth rate of fast-growing tumors and is probably responsible for the IR abnormalities observed. The most remarkable aspect of IR imaging is that these abnormalities often precede mammographic abnormalities associated with breast cancer by years and sometimes even decades [1, 2]. We therefore believe that the higher metabolic rate of faster-growing tumors and the associated increase in local vascularization causes most of the abnormalities seen in the IR image of breast cancer patients. Since faster-growing tumors are known to have a poorer prognosis, their association with abnormal IR imaging results offers significant prognostic value for breast cancer patients.

Comparison of IR images from the first-generation scanning IR imaging systems to the results from a second-generation IR imaging system clearly showed the higher quality of the images from the newer technology. The improvement was due to the greater thermal sensitivity, greater number of elements, and greater dynamic range of the focal-plane, staring array imager. The proportion of patients determined to be at increased risk of breast cancer is probably a little high and therefore yields lower specificity, as determined with the second-generation IR system. However, the strength of using an IR index is not in the overall proportion of patients who are at increased risk, but with its ability to create a series of groups of patients with semiquantitative increasing risk. This grading can be done by adjusting the weight of the different asymmetric IR abnormalities used in creating the IR index. In future studies, we will be able to address the independent values of the six IR abnormalities and to create an index where each will be appropriately weighted. This process of weighing the independent variables, the different asymmetric IR abnormalities, is not possible with the three-level subjective analysis used with the scanning IR system.

In this study, the lack of association between IR imaging results and known risk factors in patients being screened for breast cancer confirms that IR results are independent of known risk factors. Therefore, in light of the evidence [1, 2, 3] showing a strong association of asymmetric IR abnormalities with a high risk of getting breast cancer, it can be concluded that such images are a significant independent risk factor for breast cancer.

The objective measurements from our initial image analysis need to be done on a larger database of focal-plane images to determine their utility. Hopefully, by removing the subjectivity of current image-analysis methods, there will be an improvement in risk assessment, detection, and treatment of breast cancer. Methods of analysis of the breast IR images need to be developed that reduce perspective distortions that are inherent to imaging of three-dimensional shapes and also to overcoming the lack of ideal body symmetry due to both natural asymmetry and also the spatial orientation of the imager to the subject. Finally, the whole analysis must be automated, as highly interactive analysis is not conducive to the typical practice of medicine.

Conclusions

The role of IR imaging in breast cancer risk assessment, detection, diagnosis, and prognosis has not been fully determined. The use of IR imaging for detection and diagnosis of breast cancer is limited by an inability to localize the tumor. Therefore, IR imaging can only be used to complement mammography and physical exam in the detection and diagnosis of breast cancer.

IR imaging does have an important role in screening for breast cancer risk assessment. The evidence presented in this article further demonstrates that women with abnormal IR images are at increased risk, approaching 30%, of developing breast cancer. These high-risk patients should be followed closely with IR imaging, mammography, and clinical examination in order to detect their cancers early, when there is a higher probability of cure. IR imaging also has prognostic value for breast cancer patients. Further study in Stage I breast cancer patients is needed to see if IR imaging results can be integrated with the results of other prognostic indicators, when deciding whether to give adjuvant chemotherapy. Additional studies are needed to better define the role of improved second-generation IR imaging instrumentation and computer-assisted image-analysis techniques.

Acknowledgments

Partial financial support was provided by the Breast Foundation, Baton Rouge, LA, and through a SBIR contract with the Army Night Vision Laboratory. We are also indebted to Raytheon for kindly lending us an Amber IR imaging system for this study.



Jonathan F. Head is the director of research at the Mastology Research Institute of the Elliott Mastology Center and director of research and development of Medical Thermal Diagnostics in Baton Rouge, LA. He obtained his B.S. in zoology from Syracuse University, his M.A. in biology from Brooklyn College of CUNY, and his Ph.D. in biology from Fordham University. He was in the Division of Cell Biology of Naylor Dana Institute for Disease Prevention of the American Health Foundation, NY (1974-1978); the Department of Immunology at Cornell University Medical School, NY (1978); the Depart-

ment of Pediatrics at Mt. Sinai Medical School, NY (1978-1987); and the director/department head of tumor cell biology at the Center for Clinical Sciences, International Clinical Laboratories, TN (1986-1988). In 1988, he moved to Baton Rouge, LA, to become president of the Mastology Research Institute and is both the director of research and director of the clinical laboratory. He has appointments in the Department of Biochemistry at Tulane University School of Medicine and the Department of Physical Sciences at Delta State University.



Fen Wang was born in Xingjiang, China, and graduated from Beijing Medical University in 1984. After medical school he completed a surgical residency in China. As an exchange scholar he went to Essen University Medical School, Germany, for three years and studied applications of infrared imaging in medicine, specifically the human female breast. He received a Ph.D. from Essen University after finishing his dissertation. In 1991 he joined the Mastology Research Institute of the Elliott Mastology Center in Baton Rouge, LA. His cancer research activities include growing primary tissue culture from breast cancer tissue for cancer vaccinations, investigating the complexes of chemotherapeutic agents bound to human transferring for cancer patient chemotherapy, and the study of iron metabolism in cancer cells. After finishing a one-year surgical residency at the University of South Alabama Medical Center in Mobile, AL, he is now doing a radiation oncology residency at the Kansas University Medical Center in Kansas City, MO.



Charles A. Lipari received the B.S. and M.S. in electrical engineering from the University of S.W. Louisiana in 1975 and 1978, respectively. In 1989 he received his Ph.D. in electrical engineering from Louisiana State University in Baton Rouge. He worked as a digital systems engineer for Texas Instruments from 1978 to 1984, where he was part of a design team developing array processor technology for seismic signal processing. Before returning to an academic career, he worked for Thermalscan Inc., where he was chief engineer for the development of a pavement

image processing system for surveying distress in road beds. In 1990, he joined Arizona State University, where he is now an assistant professor in the Department of Electronic and Computer Engineering Technology. He is currently working on projects to develop an image-processing system for the recognition of breast cancer using infrared imaging. Other interests include the use of reconfigurable computing elements for high-speed image processing and computer vision.



Robert L. Elliott was born in Greenville, MS, in 1936. He received his M.D. from the University of Mississippi School of Medicine in 1961. He did a residency in general and thoracic surgery from

1961 to 1967 at the University of Mississippi School of Medicine and did a traineeship in electron microscopy at Washington University during his residency. He was in private practice of general and thoracic surgery from 1967 to 1973 in Anniston, AL. In 1974, he moved to Baton Rouge, LA, and founded the Elliott Mastology Center, which consists of the Breast Clinic and the Mastology Research Institute. He received his Ph.D. from LaSalle University in 1994. He limits his practice to the areas of prevention, early diagnosis, treatment, and research of diseases and cancer of the breast.

Address for Correspondence: Dr. Jonathan Head, Mastology Research Institute, 8221 Kelwood Drive, Baton Rouge, LA 70806. Tel: +1 225 927 2256. Fax: +1 225 927 3772. E-mail: emcmri@iamerica.net.

References

1. **Gautherie M, and Gros CM:** Breast thermography and cancer risk prediction. *Cancer* 45: 51-56, 1980.
2. **Stark AM:** The value of risk factors in screening for breast cancer. *Eur J Cancer* 11: 147-150, 1985.
3. **Head JF, Wang F, and Elliott RL:** Breast thermography is a noninvasive prognostic procedure that predicts tumor growth rate in breast cancer patients. *Ann NY Acad Sci* 698: 153-158, 1993.
4. **Isard HJ, Sweitzer CJ, and Edelman GR:** Breast thermography: A prognostic indicator for breast cancer survival. *Cancer* 62: 484-488, 1988.
5. **Gautherie M:** Thermography of breast cancer: Measurement and analysis of the *in vivo* temperature and blood flow. *Ann NY Acad Sci* 335: 383-413, 1982.